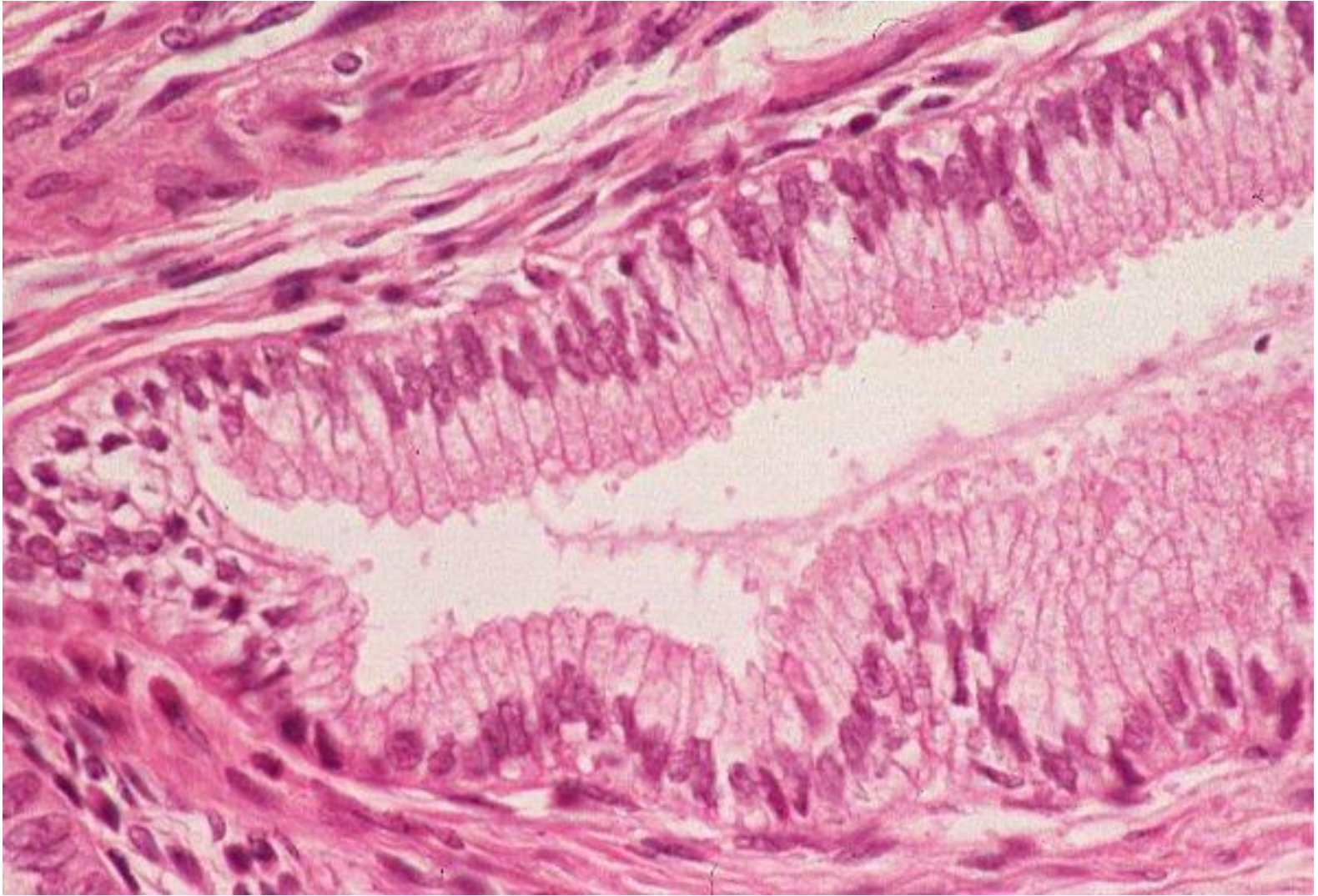


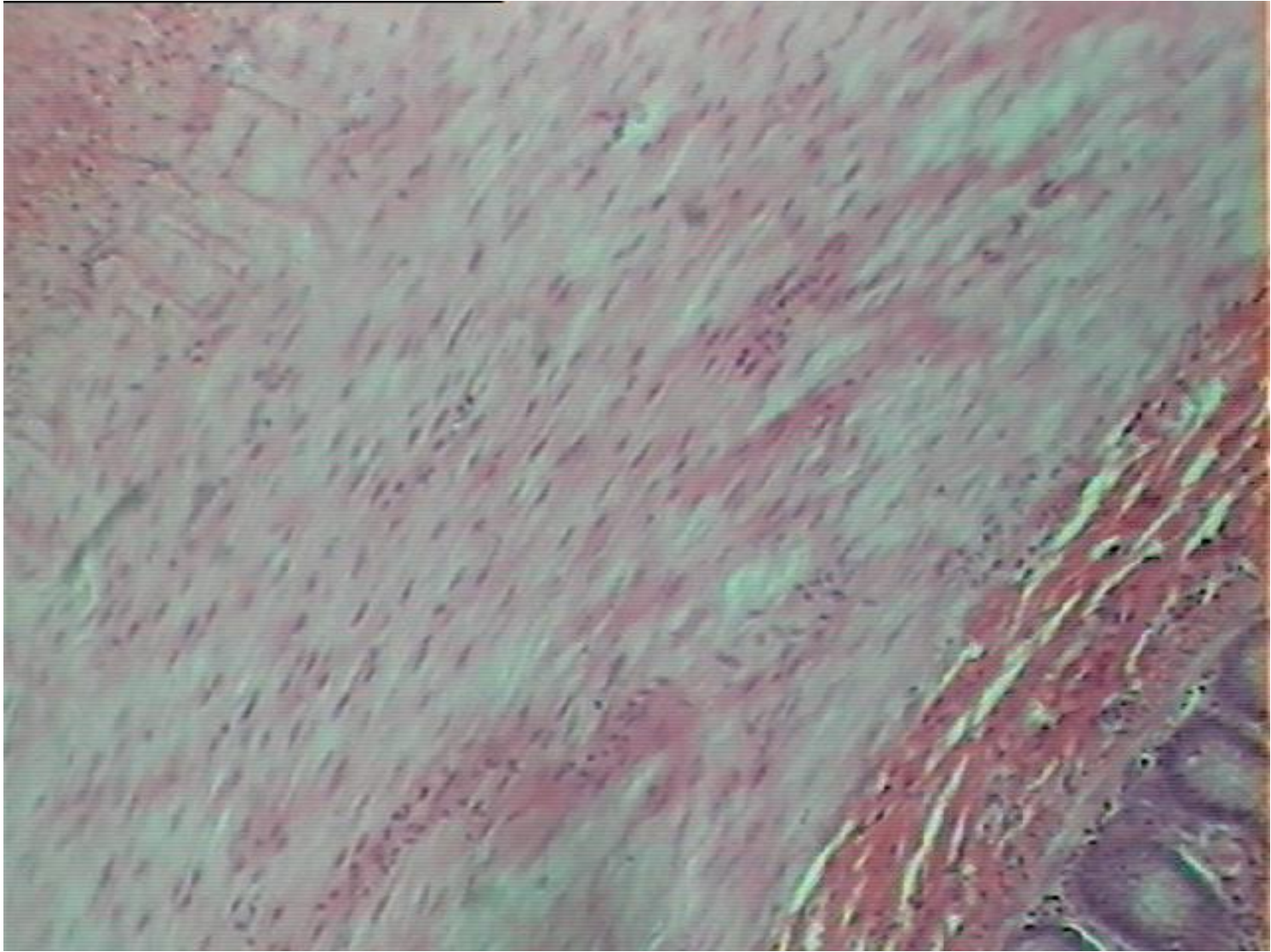
1.



Epithelium

- Columnar

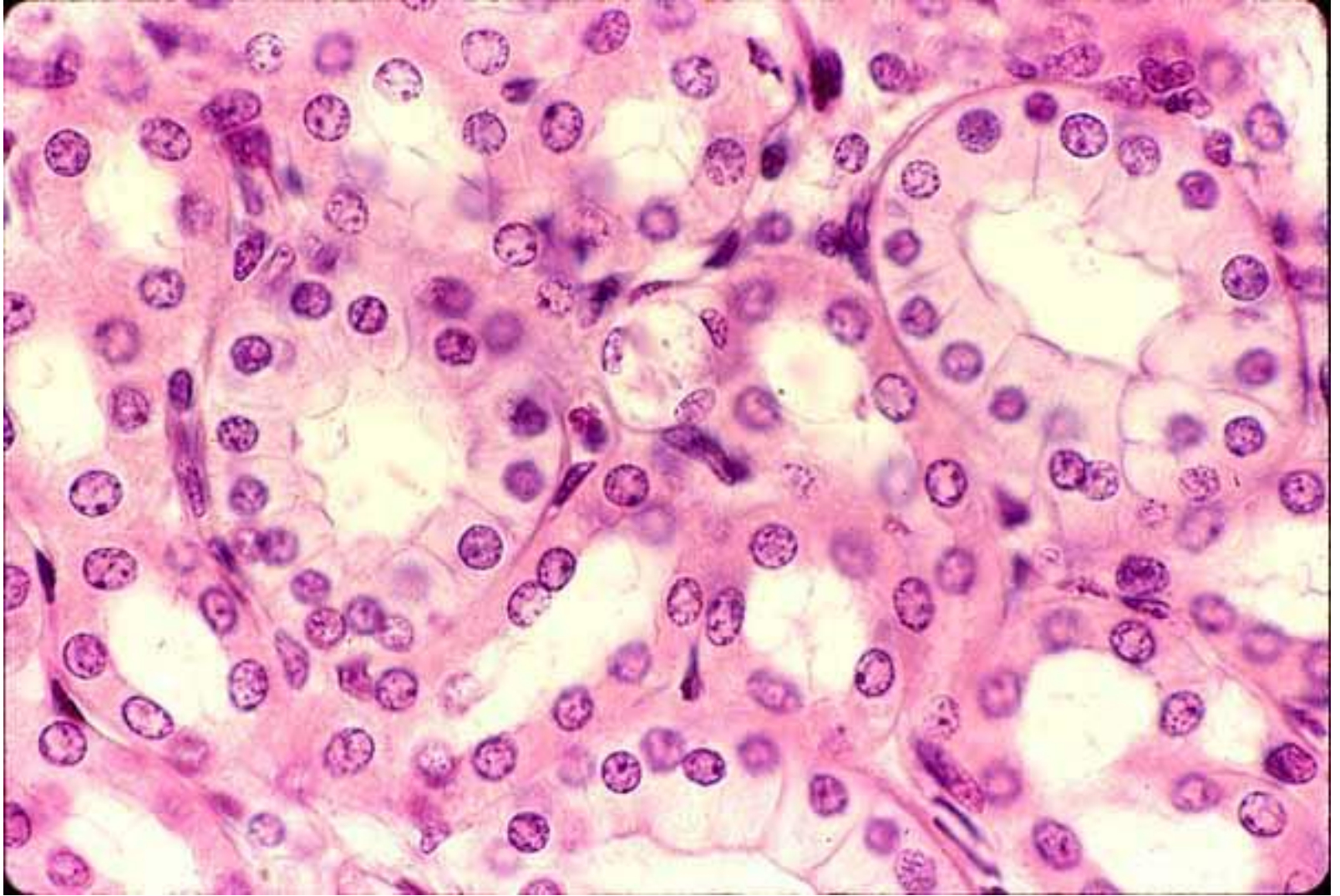
2.



Muscle

Smooth

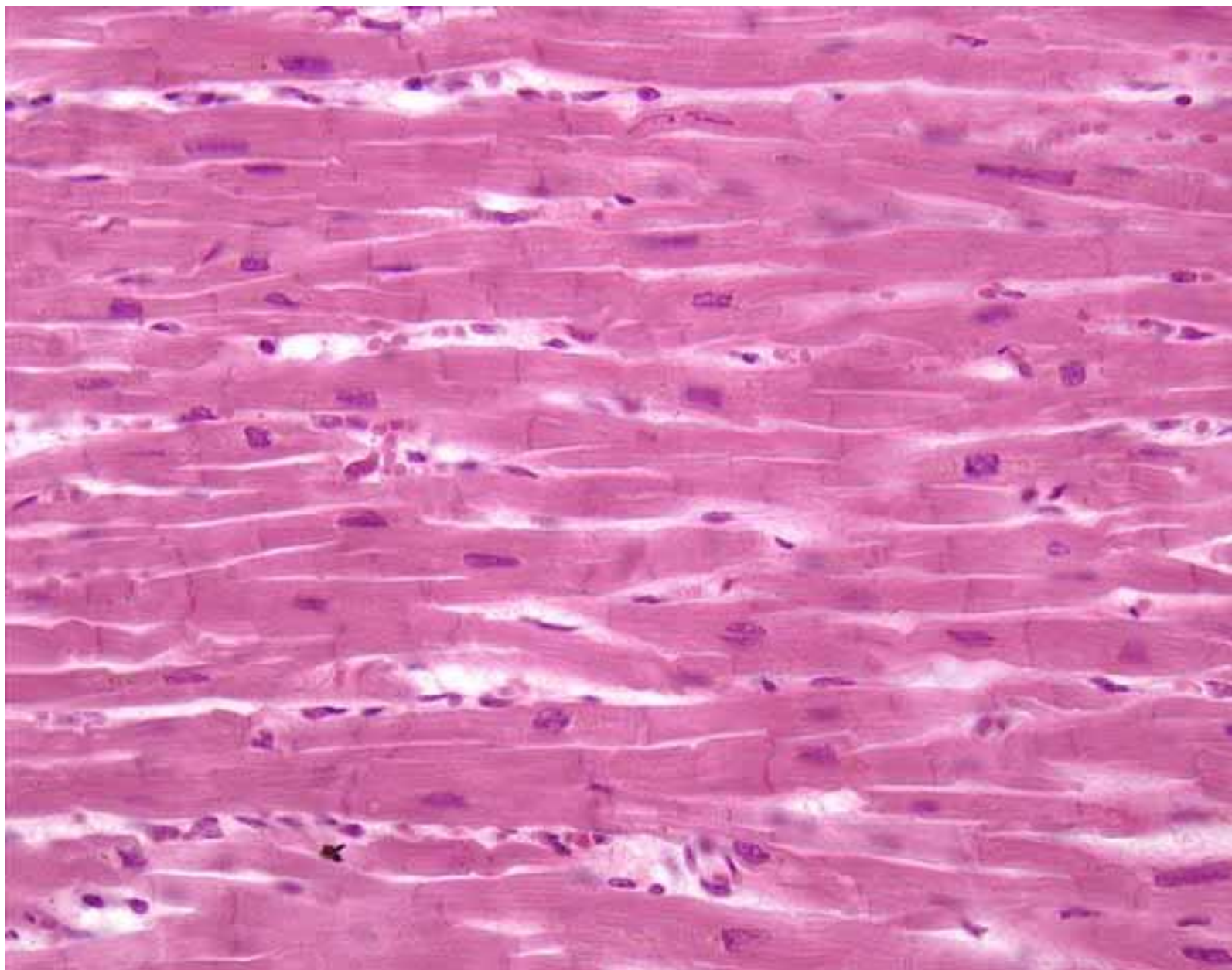
3.



Epithelium

Cuboidal

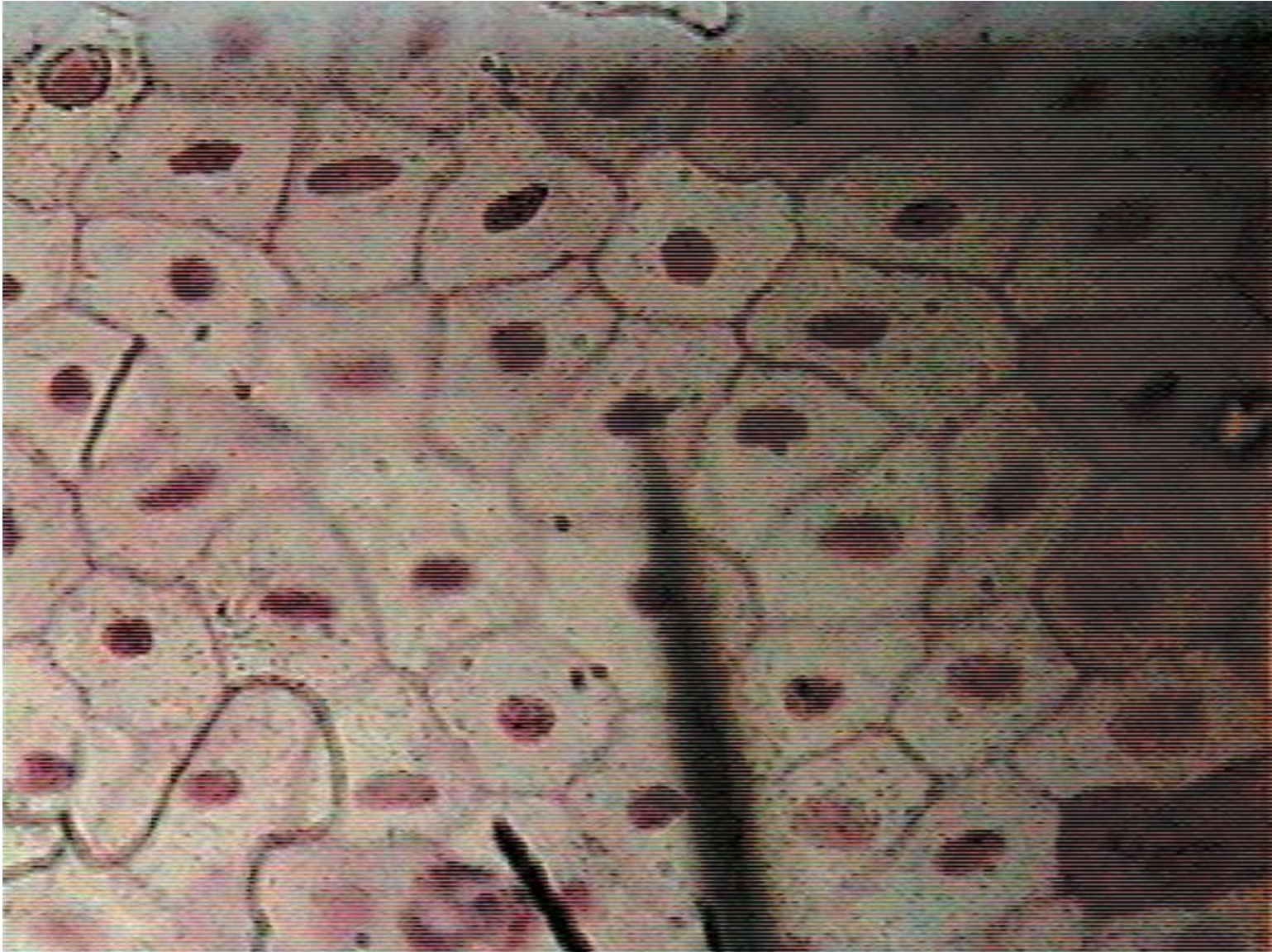
4.



Muscle

Cardiac

5.



Epithelium

Squamous

6.



Muscle

Skeletal